



Laser hemorrhoidoplasty versus Milligan-Morgan hemorrhoidectomy – short-term outcome

Poređenje hemoroidektomije laserom i hemoroidektomije metodom Milligan-Morgan – kratkoročni rezultati

Halit Maloku*, Ranko Lazović†, Hasime Terziqi‡

University of Montenegro, Faculty of Medicine, *PhD Studies, †Department of Surgery, Podgorica, Montenegro; Multi-Profile University Hospital for Active Medical Treatment and Emergency Medicine (UMHATEM), “N. I. PIROGOV”, ‡PhD study, Sofia, Bulgaria

Abstract

Background/Aim. According to the “vascular” theory, arterial inflow into the upper hemorrhoidal artery leads to venous dilatation of the hemorrhoidal plexus. Laser hemorrhoidoplasty (LHP) is a new treatment applied to outpatients in whom the hemorrhoid arterial blood flow is coagulated (nourishes by hemorrhoidal plexus) by laser. The aim of this study was to compare two groups of patients treated by two different methods: by laser (LHP) and with open surgical procedure – the Milligan Morgan (MM) method. **Methods.** This study included 200 patients with grade 3 hemorrhoidal disease older than 18 years, divided into two groups: 100 patients treated with the LHP, while the other 100 patients with the MM hemorrhoidectomy. Parameters used to compare two applied surgical methods were: duration of hospitalization, postoperative pain, the presence of bleeding and time needed to return to normal life. **Results.** The results reveal a statistically significant difference between these two methods. The level of postoperative pain was lower in the group of patients treated with the LHP compared to the group of patients treated with the MM method ($p < 0.0001$). The group treated with the LHP manifested less bleeding in comparison with the group treated with the open surgical method (MM). Length of hospitalization and duration of surgery were significantly shorter in the group treated with the LHP method than in the group treated by the MM method. **Conclusion.** According to our results, it is clear that the LHP method has many advantages over the MM hemorrhoidectomy in patients with grade 3 hemorrhoidal disease.

Key words:

hemorrhoids; laser therapy; surgical procedures, operative; postoperative period; postoperative complications.

Apstrakt

Uvod/Cilj. Prema “vaskularnoj” teoriji arterijski priliv u gornjoj hemoroidalnoj arteriji dovodi do dilatacije hemoroidalnog venskog pleksusa. Laser hemoroidoplastika (LHP) je novi postupak primenjen u ambulantom lečenju hemoroida u kojem se hemoroidalni arterijski protok krvi koji ishranjuje hemoroidalni pleksus zaustavlja laserskom koagulacijom. Cilj ove studije bio je poređenje između grupa bolesnika lečenih sa dve različite metode, laserom (LHP) i sa otvorenom hirurškom metodom – Milligan Morgan (MM). **Metode.** U ovu studiju bilo je uključeno 200 bolesnika sa hemoroidima trećeg stepena, starijih od 18 godina, od kojih je 100 bilo tretirano LHP metodom, dok je ostalih 100 bolesnika tretirano Milligan-Morgan hemoroidektomijom. Parametri koji su se koristili za poređenje dve hirurške metode bili su: dužina hospitalizacije, postoperativni bol, prisustvo krvarenja i vreme potrebno da se bolesnici vrate normalnom životu. **Rezultati.** Rezultati su pokazali statistički značajnu razliku među metodama. Nivo postoperativnog bola bio je niži kod bolesnika u grupi lečenih LHP u odnosu na grupu bolesnika lečenih MM metodom ($p < 0,0001$). U grupi tretiranoj metodom LHP, krvarenje je bilo manje u odnosu na grupu koja je tretirana otvorenom hirurškom metodom (MM). Trajanje operacije, kao i dužina hospitalizacije bili su znatno kraći u grupi sa hemoroidoplastikom (LHP) u odnosu na grupu sa hemoroidektomijom (MM metoda). **Zaključak.** Dobijeni rezultati upućuju na značajne prednosti LHP metode u odnosu na metodu Milligan Morgan kod bolesnika sa hemoroidima trećeg stepena.

Ključne reči:

hemoroidi; hirurgija laserom; hirurgija, operativne procedure; postoperativni period; postoperativne komplikacije.

Introduction

Hemorrhoidal disease is ranked much higher than the rectum and colon diseases. Today, the presence of hemorrhoidal disease is evaluated to be between 2.9%–27.9% among the worldwide population and 4% are symptomatic. One third of the total number of patients ask for medical advice^{1,2}.

Based on the Gauss method the highest incidence rate of the disease is found among patients aged between 45 and 65 years, while the incidence rate of the disease decrease after 65 years of age^{3,4}. Men are more often affected than women⁵.

Anorectum vascular cushions together with the internal anal sphincter are essential in maintaining continence by supporting the soft tissue in the closure of the anal canal^{6,7}. Different options for the treatment of symptomatic hemorrhoids varied over the time. The measures include a variety of conservative medical procedures, non-surgical treatment and various surgical methods. Various non-surgical procedures include rubber band ligation (RBL), sclerosing injection, cryotherapy, infrared coagulation, laser therapy and coagulation by diathermy as well as a therapeutic procedure that can be applied without anesthesia. The non-surgical methods mentioned above are considered as primary option in hemorrhoids level I–III treatment⁸. If conservative methods are not successful, patients are treated surgically. Significant factors in setting the indications for surgical treatment are: papilla hypertrophy, associated fissure, thrombotic enlargements and recurrent symptoms after RBL. The Milligan-Morgan (MM) hemorrhoid ectomy is the gold standard and often applied procedure in the United Kingdom⁹.

Hemorrhoidectomy is an extremely painful procedure. Pain is caused by damaging the tissue of the anal region which is richly innervated by nerve endings. Postoperative pain is the most common problem in surgical treatment.

The aim of this study was to compare the postoperative results: pain, bleeding, infection, recidive, urinary retention, hospitalization period, return to normal life and satisfaction of patients after treatment with the laser hemorrhoidoplasty (LHP) or MM methods.

Methods

This comparative and prospective study included 200 patients with grade 3 hemorrhoidal disease where 100 patients were treated with the LHP while the other 100 patients were treated with the MM hemorrhoidectomy method.

The study was done at the Surgical Clinic ALOKA, Pristina, from June 2014 to May 2015. Control and follow-up of the patients was done during week 1, 2, 3, 4 and after 8 weeks (60 days).

All operations were performed by one surgeon. General anesthesia was applied on a patient's request. Preoperative treatment such as proctoscopy and sigmoidoscopy followed by the laser procedure using Bio-Litec equipment were included in all cases treated by the LHP method.

Exclusion criteria were applied in case when a patient was younger than 18 years as well as when a patient had he-

morrhoids and another condition in the anus (fissure, fistula, perianal abscess).

The perianal area was shaved and patients from both groups received cleansing with bisocodyl supp. 1 × 2. The patients were treated in gynecological position. Anoscope was applied and followed by the laser procedure using Bio-Litec equipment with a diode (Bonn, Germany), which operates at a wavelength of 980 ± 30 nm with optical power of 8–15W (Pulse Mode) that is sufficient for the denaturation and reduction of hemorrhoidal plexus (Figure 1).




Fig. 1 – Laser, diode 980-nm and anoscope.

In the LHP technique, the energy created by the laser was transmitted to the place we wanted to treat through the optical fiber. LED lighting equipment can help to determine the diameter of the shape and the length of the treatment as well as the duration of the procedure. First, we provided a small skin incision about 1 to 1.5 cm distance from the anal edge concentrically for about 4 to 5 mm and performed the perianal skin/anoderms, tunneling with scissors to the edge of the internus. The pointed laser probe was then quickly driven subanoderms/ submucosally until it reached the area underneath the distal rectal mucosa. This was followed by about six pulses (adjusted to respective dimensions of the piles) of approx. 30 joule per node; a half of which was

highly submucosal and the other half highly intranodal. The tissue response could be clearly discerned by the light reduction: contraction was occasionally observed immediately (Figure 2). Hemorrhoidal nodes were not treated with the LHP method since this method was applied only to the hemorrhoidal plexus without ligature or any other procedure.

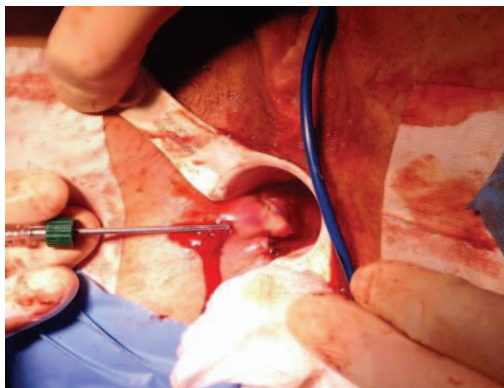

Fig. 2 – Laser hemorrhoidoplasty procedure.

In the MM technique all the patients were operated on in the lithotomy (prone) position and general anesthesia.

A V-shaped incision by the scalpel in the skin around the base of the hemorrhoid was made using scissors dissection in the submucous space to strip the entire hemorrhoid from its bed (Figure 3). The dissection was carried cranially to the pedicle which was ligated with a strong catgut and the distal part excised. Other hemorrhoids were similarly treated, leaving a skin bridge amid to avoid stenosis (Figure 3). The wound was left open and a hemostatic gauze pad was left in the anal canal.

Postoperative pain, bleeding, delayed healing and acute urine retention were common complications.

Both the LHP and MM hemorrhoidectomy were performed under general anesthesia.

Assessment of postoperative pain

Postoperative pain was evaluated using the visual analogue scale (VAS 0-10) where 0–1 represented no pain, 1.1–3 less pain intensity, 3.1–7 pain of medium intensity, 7.1–9 pain of high intensity and 9.1–10 strong, unbearable pain. The VAS protocol was performed on the days 1, 7, 14, 21, 30, and 60 after surgery.

All the patients received analgesics - diclofenac 75 mg 2×1 intravenously (*iv*) if needed. In case of persisting pain, trodnadol 50 mg 3×1 *iv* were used as needed. Control of the patients for bleeding was carried out in weeks 1, 2, 3 and 4, and during the following first and second month after treatment as well as at any time in case of major bleeding.

Statistical analysis was performed by the χ^2 test and Mann-Whitney test.

Results

This prospective study was based on 200 patients where 121 (60.5%) were males and 79 (39.5%) were females. There

were two different methods used in their treatment – the LHP and MM hemorrhoidectomy. From the overall number of patients (200) with grade 3 hemorrhoids, a half (100) was treated with the LHP method. The average age of the patients was 47 ± 12.6 years (range 24–70 years). The procedure was performed in 57 males and 43 females. The MM procedure was applied on other 100 patients out of whom 64 were males and 36 females aged 49 ± 12.3 years. There was no difference between these two groups of patients regarding age. Also, we found homogeneity in the groups regarding gender where the χ^2 test showed 0.88 value.

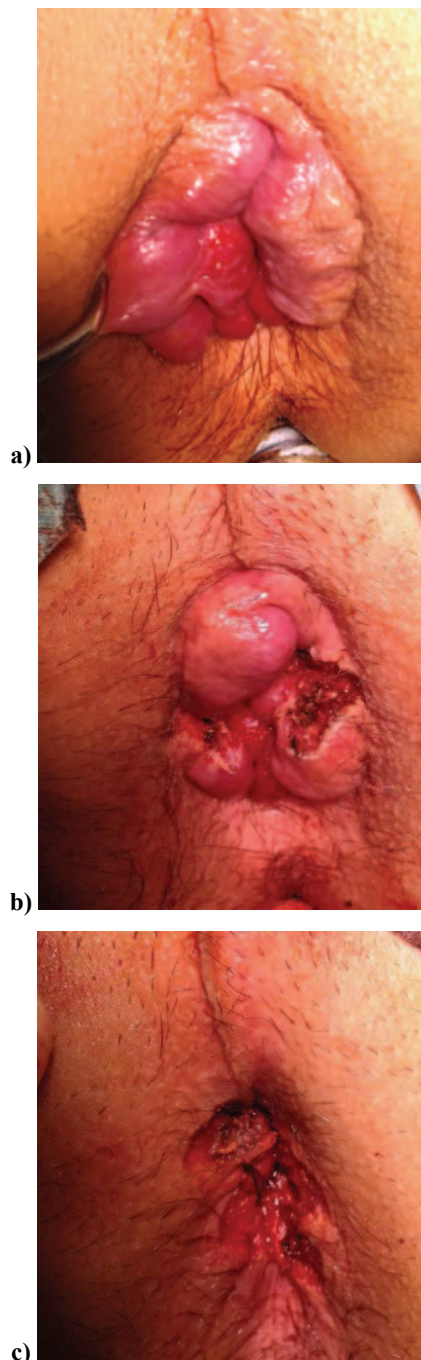

Fig. 3 – Hemorrhoids: a) before the operation; b) during the operation; c) after the operation.

Figure 4 shows in detail the results of postoperative pain development in two groups treated with two different methods: the LHP and the MM method.

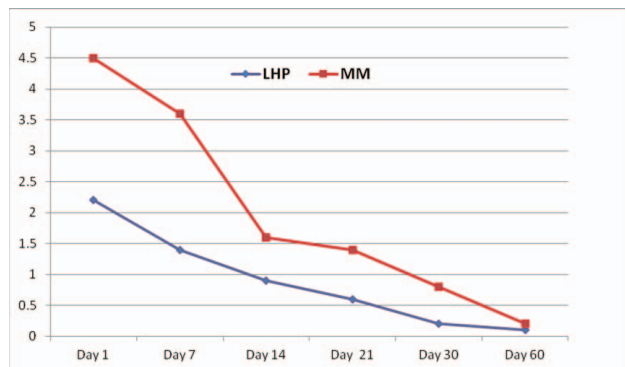


Fig. 4 – Results of postoperative pain in the laser hemorrhoidoplasty (LHP) and Milligan Morgan (MM) groups according to VAS during 60 days after the intervention ($p < 0.0001$).

As we can see, after hemorrhoidal intervention with the LHP method, the level of postoperative pain on the day 1 was on average 2.2 (SD \pm 0.3) (VAS). On the other hand, after hemorrhoidal intervention with the MM method, the average pain level was 4.5 (SD \pm 0.8). On the day 30, in the LHP group, the average level of pain or VAS was 0.2 (SD \pm 0.1) while in the MM group it was 0.8 (\pm 0.2 SD). The same values were after 60 days. Postoperative pain was significantly lower in the LHP group than in the MM group ($p < 0.0001$).

During the first days after the intervention, 13% of the patients in the LHP group and 77% of the patients in the MM group had small scale bleeding which was statistically significant ($p < 0.0001$). Bleeding was present with statistically significant difference ($p < 0.001$) on the day 7 (10% of the patients in the LHP group and 33% of the patients in the MM group).

On the day 60 after the intervention, there was no bleeding in any of the groups (Figure 5).

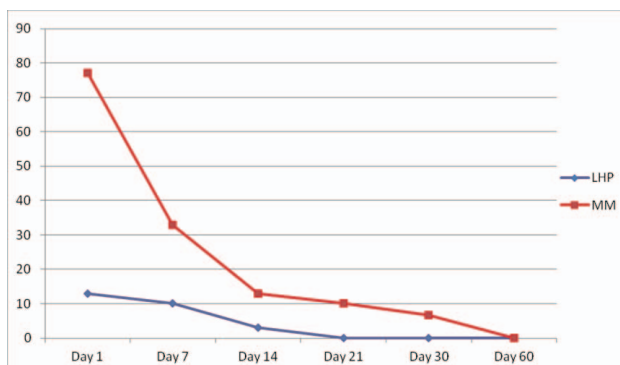


Fig. 5 – Mean bleeding during 60 days after hemorrhoidal treatment by laser hemorrhoidoplasty (LHP) and hemorrhoidectomy (Milligan Morgan method – MM).

Using the Mann-Whitney test, we got a statistically significant difference in length of hospitalization by the groups ($U = 2545.0$, $p < 0.0001$).

The average recovery time for the patients treated with the LHP procedure was 17.2 days (SD \pm 4.9 days), ranging from 5 to 30 days, while for the patients treated with the MM haemorrhoidectomy, the average recovery time was 19.2 days (SD \pm 2.9 days), ranging from 14 to 35 days. The Mann-Whitney test showed a statistically significant difference regarding the time needed for patients per group to return to normal life ($U = 1829.4$; $p < 0.003$).

The average duration of hemorrhoidectomy with the LHP was 15.9 minutes (SD \pm 1.9 minutes), in the range of 10–20 minutes and with the MM procedure, it was 27.2 minutes (SD \pm 6.5 minutes), ranging from 12 to 60 minutes. The results showed a statistically significant difference ($p < 0.0001$) between the groups regarding the duration of the surgery.

The costs of the treatment with the LHP were higher than that of the MM method because the fiber optic LED is used only once which is required for this type of treatment, is used.

Discussion

The LHP is used for a delicate treatment of advanced hemorrhoids, in conditions of adequate anesthesia where endoluminal laser coagulation („welding”) was made in hemorrhoidal vessels. Since the energy of the laser beam is applied solely only in hemorrhoidal vessels, no damage was done to anoderma and mucosa (the surrounding healthy tissue)^{10–13}. In the treatment with this method, no foreign materials (buckles and surgical sutures) are used, which greatly contributes to elimination of postoperative pain and a risk of postoperative stenosis (narrowing) of the anal canal^{14,15}. Healing and recovery are excellent and fast, practically imperceptible, due to the absence of cuts, open wounds and stitches^{3,16–18}.

After the MM hemorrhoidectomy, patients usually remain in hospital for 3–5 days and leave with considerable discomfort¹⁹. After the treatment with the LHP hemorrhoidectomy, typically, a patient can return to home the same day. After 3 or 4 days he/she are very comfortable without pain or any difficulty with their bowels, and they can return to their normal routine in 7–10 days after the intervention²⁰. Simply, painless hemorrhoidectomy results in satisfaction of both the patients and surgeons^{16,21,22}. Open surgical hemorrhoidectomy is the most widely used procedure in the surgical management of hemorrhoids. However, the MM method is associated with considerable complications including pain, bleeding and infection which can result in longer hospitalization^{3,16,19,23}. Our results showed significantly lower pain in the group after the LHP than in the group after the MM procedure. Postoperative pain is the most important complication that bothers patients and makes them reluctant to undergo surgical treatment. Our study showed that postoperative pain in the first month was significantly lower after the LHP than after the open hemorrhoidectomy which is similar to the results of some other studies^{3,16,18,24}. We found that the LHP procedure caused minor bleeding, which stopped in a much shorter period when compared to hemorrhage

after the MM method²². According to relevant literature²¹, in 71% of the cases bleeding lasted less than a week. None of the patients required surgical intervention nor blood transfusions which is in agreement with our results^{21,22}. According to literature sources²⁵ infection occurs in 5%–15% of patients, and relapse in 5%–30%^{16,17,24,25,26}. Not a single case of urinary retention and no need to set a urinary catheter were registered in comparison to some literature data showing 0%–16% of cases with urinary retention and catheterization^{21,27}. Average hospitalizations was 2.1 days in case of the MM method and 1 day after the LHP. According to Voigtsberger et al.²⁰, hospitalization lasted for 3 days. Financial costs are higher for the LHP treatment than for the MM procedure²⁸. Crea et al.¹⁶ suggest that ambulatory treatment by

the LHP lowers the cost of anesthesia and enables treatment in hospitals which have no equipment required for general anesthesia²⁸. According to our analysis of the cases in both groups, none of the patients accepted the treatment in local anesthesia, which means that general anesthesia was preferred. This confirms the fact that patients chose a painless method.

Conclusion

Our results show that the LHP as a minimally invasive method is more preferable than the MM procedure because of significantly lower postoperative pain, bleeding, and the duration of surgery.

R E F E R E N C E S

- Johanson JF, Sonnenberg A. The prevalence of hemorrhoids and chronic constipation. An epidemiologic study. *Gastroenterology* 1990; 98(2): 380–6.
- Rogozina VA. Hemorrhoids. *Eksp Klin Gastroenterol* 2002; (4): 93–6, 134. (Russian)
- Plapler H, Hage R, Duarte J, Lopes N, Masson I, Cazarini C, et al. A new method for hemorrhoid surgery: intrahemorrhoidal diode laser, does it work? *Photomed Laser Surg* 2009; 27(5): 819–23.
- Parks AG. De haemorrhoids; a study in surgical history. *Guys Hosp Rep* 1955; 104(2): 135–56.
- Keighley MR, Williams NS. *Surgery of the anus, rectum and colon*. London: WB Saunders; 1999.
- Haas PA, Fox TA Jr, Haas GP. The pathogenesis of hemorrhoids. *Dis Colon Rectum* 1984; 27(7): 442–50.
- Thomson WH. The nature of haemorrhoids. *Br J Surg* 1975; 62(7): 542–52.
- MacRae HM, McLeod RS. Comparison of hemorrhoidal treatment modalities. A meta-analysis. *Di. Colon Rectum* 1995; 38(7): 687–94.
- Monson JRT, Mortenson NJ, Hartley J. Procedures for Prolapsing Hemorrhoids (PPH) or Stapled Anopexy. Consensus Document for Association of Coloproctology of Great Britain and Ireland. *ACPGBI*; 2003.
- Bleday R, Pena JP, Rothenberger DA, Goldberg SM, Bals JG. Symptomatic hemorrhoids: Current incidence and complications of operative therapy. *Dis Colon Rectum* 1992; 35(5): 477–81.
- Sardinha CT, Corman ML. Hemorrhoids. *Surg. Clin North Am* 2002; 82(6): 1153–67, vi.
- Goligher J, Duthie H, Nixon H. *Surgery of the anus rectum and colon*. 5th ed. London: Baillière Tindall; 1984.
- Salfi R. A new technique for ambulatory hemorrhoidal treatment. Doppler-guided laser photocoagulation of hemorrhoidal arteries. *Coloproctology* 2009; 31(2): 99–103.
- Chia YW, Darzi A, Speakman CT, Hill AD, Jameson JS, Henry MM. CO2 laser haemorrhoidectomy--does it alter anorectal function or decrease pain compared to conventional haemorrhoidectomy? *Int J Colorectal Dis* 1995; 10(1): 22–4.
- Barchy L. Best option for evaluating and treating hemorrhoids. *BMJ* 2008; 336: 380–3.
- Crea N, Pata G, Lippa M, Chiesa D, Gregorini ME, Gandolfi P. Hemorrhoidal laser procedure: short- and long-term results from a prospective study. *Am J Surg* 2014; 208(1): 21–5.
- Naderan M, Shoar S, Nazari M, Elsayed A, Mahmoodzadeh H, Khorgami Z. A Randomized Controlled Trial Comparing Laser Intra-Hemorrhoidal Coagulation and Milligan-Morgan Hemorrhoidectomy. *J Invest Surg* 2016; 2: 1–7.
- Leardi S, Pessia B, Mascio M, Piccione F, Schietroma M, Pietroletti R. Doppler-Guided Transanal Hemorrhoidal Dearterialization (DG-THD) Versus Stapled Hemorrhoidopexy (SH) in the Treatment of Third-Degree Hemorrhoids: Clinical Results at Short and Long-Term Follow-Up. *J Gastrointest Surg* 2016; 20(11): 1886–90.
- Milligan ET, Morgan CN, Jones LE, Officer R. Surgical anatomy of the anal canal and the operative treatment of hemorrhoids. *Lancet* 1937; 2: 1119–24.
- Voigtsberger A, Popovicova L, Bauer G, Werner K, Weitschat-Benser T, Petersen S. Stapled hemorrhoidopexy: functional results, recurrence rate, and prognostic factors in a single center analysis. *Int J Colorectal Dis* 2016; 31(1): 35–9.
- LaBella GD, Main WP, Hussain LR. Evaluation of transanal hemorrhoidal dearterialization: A single surgeon experience. *Tech Coloproctol* 2015; 19(3): 153–7.
- De Nardi P, Tamburini AM, Gazzetta PG, Lemma M, Pascariello A, Asteria CR. Hemorrhoid laser procedure for second- and third-degree hemorrhoids: Results from a multicenter prospective study. *Tech Coloproctol* 2016; 20(7): 455–9.
- Sammarco G, Ferrari F, Carpino A, Russo E, Vescio G, Ammendola M, et al. PPH vs Milligan-Morgan: Early and late complications in the treatment of haemorrhoidal disease with circumferential prolapse. *Ann Ital Chir* 2014; 85(5): 464–.
- Majeed S, Naqvi SR, Tariq M, Ali MA. Comparison of Open and Closed Techniques of Haemorrhoidectomy in Terms of Post-Operative Complications. *J Ayub Med Coll Abbottabad* 2015; 27(4): 791–3.
- Avital S, Itab R, Skornick Y, Greenberg R. Outcome of stapled hemorrhoidopexy versus doppler-guided hemorrhoidal artery ligation for grade III hemorrhoids. *Tech Coloproctol* 2011; 15(3): 267–71.
- Gain Yu M. Laser Technologies in Complex Treatment of Hemorrhoids. *Novosti Khirurgii* 2013; 21(1): 94–104.
- Denoya P, Tam J, Bergamaschi R. Hemorrhoidal dearterialization with mucopexy versus hemorrhoidectomy: 3-year follow-up assessment of a randomized controlled trial. *Tech Coloproctol* 2014; 18(11): 1081–5.
- Gemici K, Okus A, Serden A. Vascular Z-shaped ligation technique in surgical treatment of hemorrhoid. *World J Gastrointest Surg* 2015; 7(1): 10–4.

Received on January 25, 2017.

Revised on April 25, 2017.

Accepted on April 27, 2017.

Online First May, 2017.